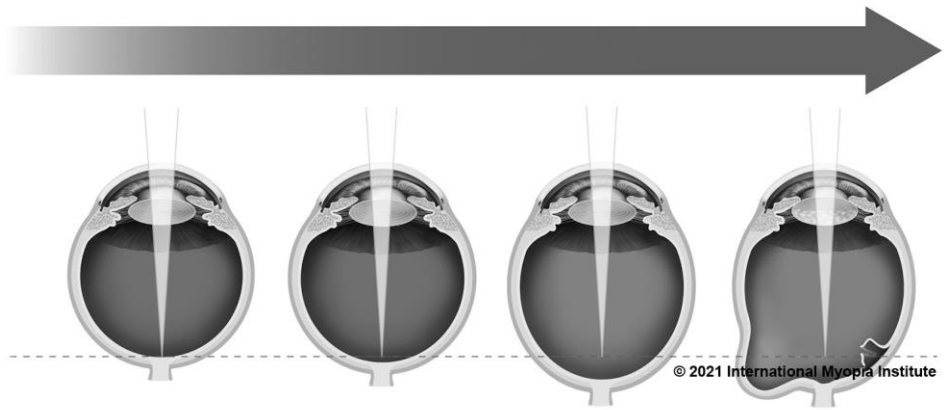

IMI CLINICAL SUMMARY

IMI Pathologic Myopia

Dr. Monica Jong PhD, BOptom

Executive Director IMI

Discipline of Optometry & Vision Science, University of
Canberra, Canberra, Australia

School of Optometry and Vision Science,
University of New South Wales, Sydney, Australia

Prof. Kyoko Ohno-Matsui MD, PhD

Advisory Board & Taskforce Chair IMI

Department of Ophthalmology, Tokyo and Medical Dental
University, Tokyo, Japan

Pathologic myopia is a major cause of visual impairment worldwide and is distinctly different from 'high myopia'. 'Pathologic myopia' is defined by a presence of typical complications in the fundus (posterior staphyloma or myopic maculopathy equal to or more serious than diffuse choroidal atrophy) and often occurs in eyes with high myopia; however, its complications, especially posterior staphyloma, can also occur in eyes without high myopia (myopic refractive error of at least -6.00 D or worse).

IMI DEFINITION OF PATHOLOGIC MYOPIA:

Excessive axial elongation associated with myopia that leads to structural changes in the posterior segment of the eye (including posterior staphyloma, myopic maculopathy, and high myopia-associated optic neuropathy) and that can lead to loss of best-corrected visual acuity.

PREVALENCE AND RISK FACTORS FOR PATHOLOGIC MYOPIA

- Pathologic myopia affects up to 3% of the world's population, with **ethnic differences** in the prevalence of the disease.
 - Approximately 1%-3% of Asians and 1% of Caucasians have pathologic myopia.
- The prevalence of pathologic myopia is 1%-19% in the low-to-moderate myopia (up to -3.00 D) population, but its prevalence 50%-70% in those with **high myopia**.
- The prevalence of pathologic myopia is low in children and adolescents, but **increases with age and spherical equivalent**.
 - In individuals with high myopia **aged 40 years or older**, there is an increase in prevalence and severity of myopic maculopathy.

- It is unclear whether genes responsible for pathologic myopia are the same as those for myopia in general, or whether pathologic myopia is genetically different from other myopia.

DIAGNOSIS AND MANAGEMENT OF PATHOLOGIC MYOPIA

- Recent advances in ocular imaging have led to objective and accurate diagnosis of pathologic myopia.
 - Optical coherence tomography (OCT) has revealed novel lesions like dome-shaped macula and myopic traction maculopathy.
 - Wide-field OCT has succeeded in visualizing the entire extent of large staphylomas.
- The effectiveness of new therapies for complications have been shown, such as anti-VEGF therapies for myopic macular neovascularization and vitreoretinal surgery for myopic traction maculopathy.
- New classification schemes that improve identification and management of pathologic myopia have been developed.
 - The META-PM classification system uses fundus photographs to identify various stages of myopic maculopathy (Appendix) and category 2 onwards, or presence of a “plus lesion” or posterior staphyloma is defined as pathologic myopia.
 - An OCT-based classification includes macular lesions such as myopic traction maculopathy and dome shaped macular that were not included in the META-PM system.

Currently the pathogenesis of pathologic myopia is not fully understood. The new classification systems, high resolution imaging techniques, and genetic studies will likely lead to further advances in this area for diagnosis and management of pathologic myopia. Preventing and slowing myopic progression is important to reduce the risk of developing pathologic myopia.

ACKNOWLEDGMENTS

A full list of the IMI taskforce members and the complete IMI white papers can be found at <https://myopiainstitute.org/>. The publication and translation costs of the clinical summary was supported by donations from the Brien Holden Vision Institute, Carl Zeiss Vision, CooperVision, Essilor, Alcon and OCULUS.



REFERENCE

Ohno-Matsui K, Wu P-C, Yamashiro K, et al. IMI pathologic myopia. Invest Ophthalmol Vis Sci. 2021;62(5):5.

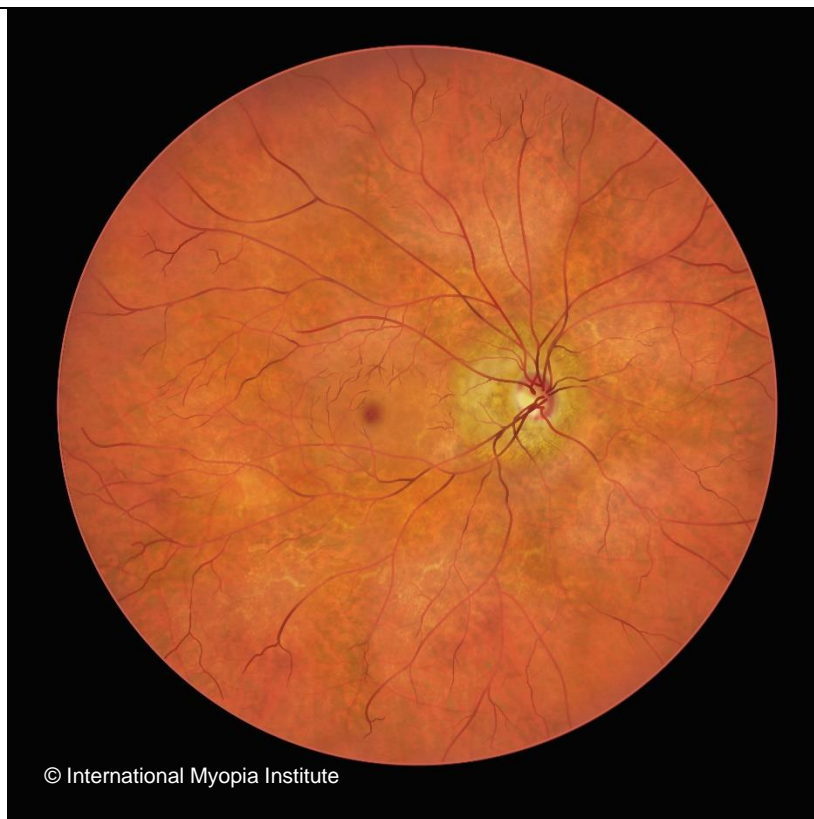CORRESPONDENCE

Brien Holden Vision Institute Ltd
Level 4, North Wing, Rupert Myers Building, Gate 14 Barker Street,
University of New South Wales, UNSW NSW 2052
m.jong@bhvi.org
+612 9385 7516

Appendix. *META-PM classification system*

Category	Retinal Signs
0	 <p data-bbox="502 1061 802 1088">© International Myopia Institute</p> <p data-bbox="735 1133 1038 1160">No myopic retinal lesions</p>
1	 <p data-bbox="502 1919 802 1946">© International Myopia Institute</p> <p data-bbox="708 2000 1066 2027">Tessellated (or tigroid) fundus</p>

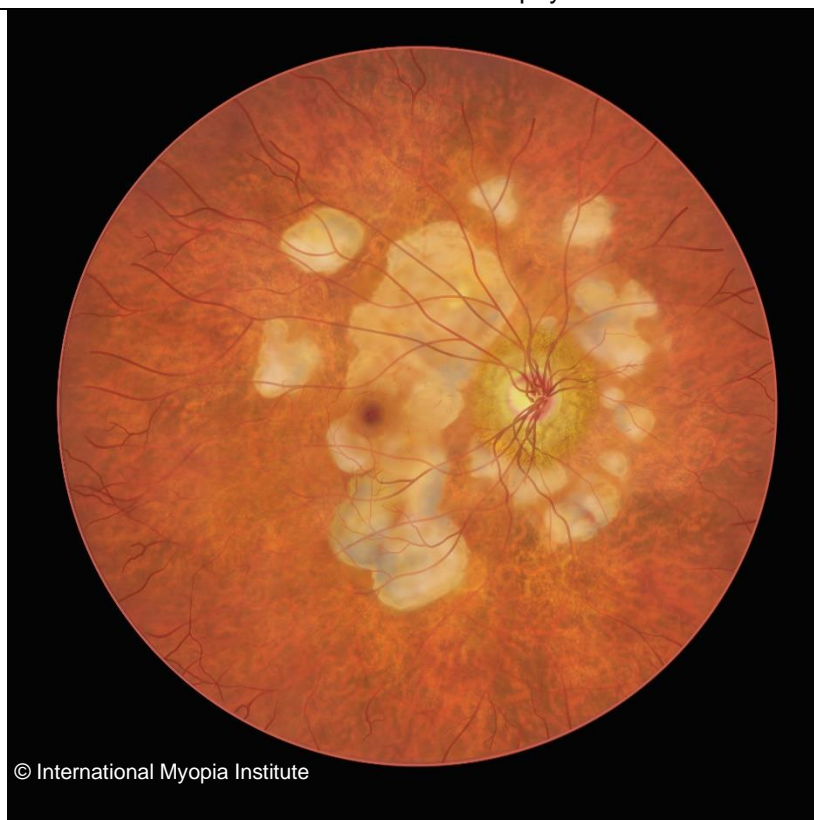
2



© International Myopia Institute

Diffuse choroidal atrophy

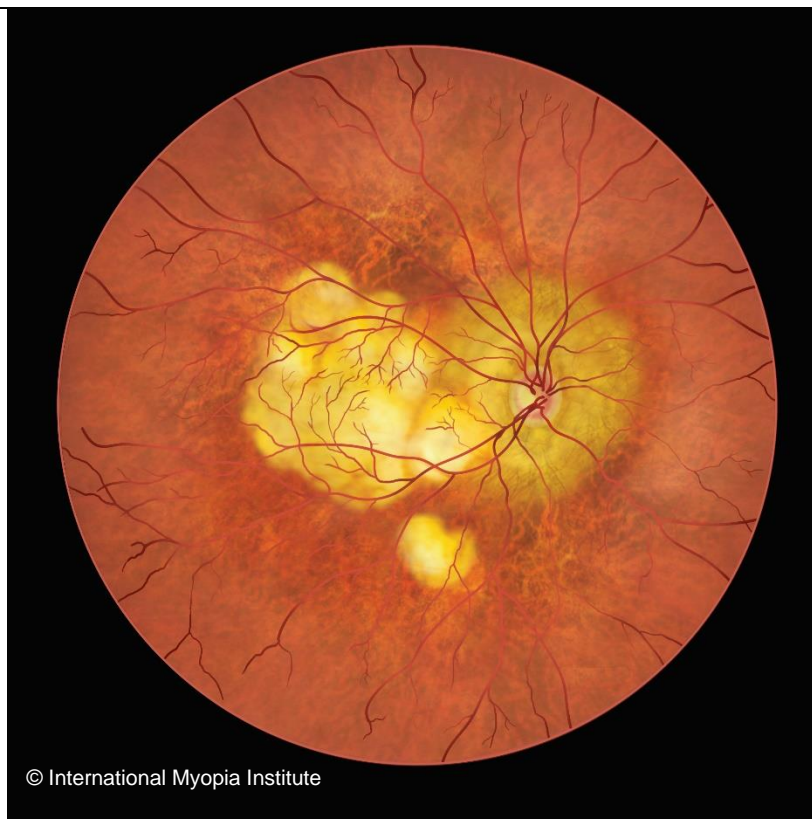3



© International Myopia Institute

Patchy choroidal atrophy

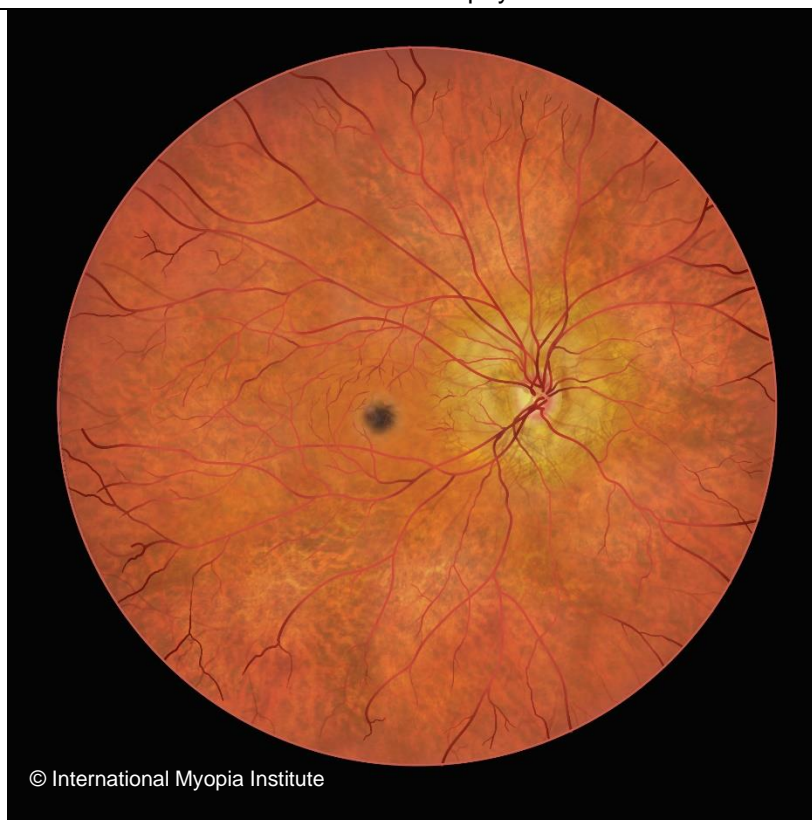4



© International Myopia Institute

Macular atrophy

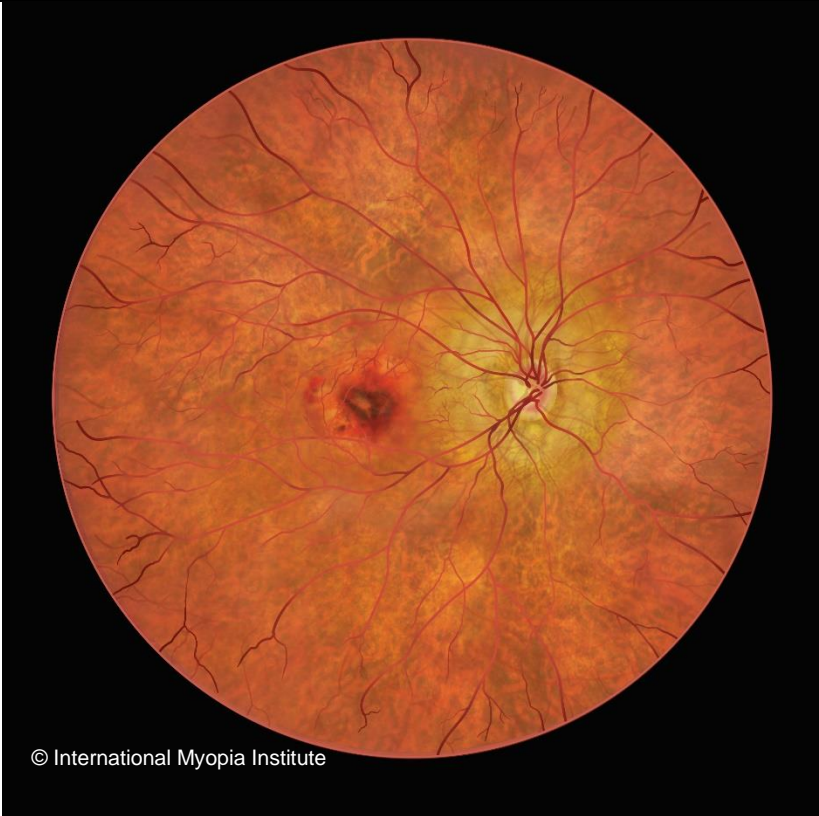**Plus
Lesions**



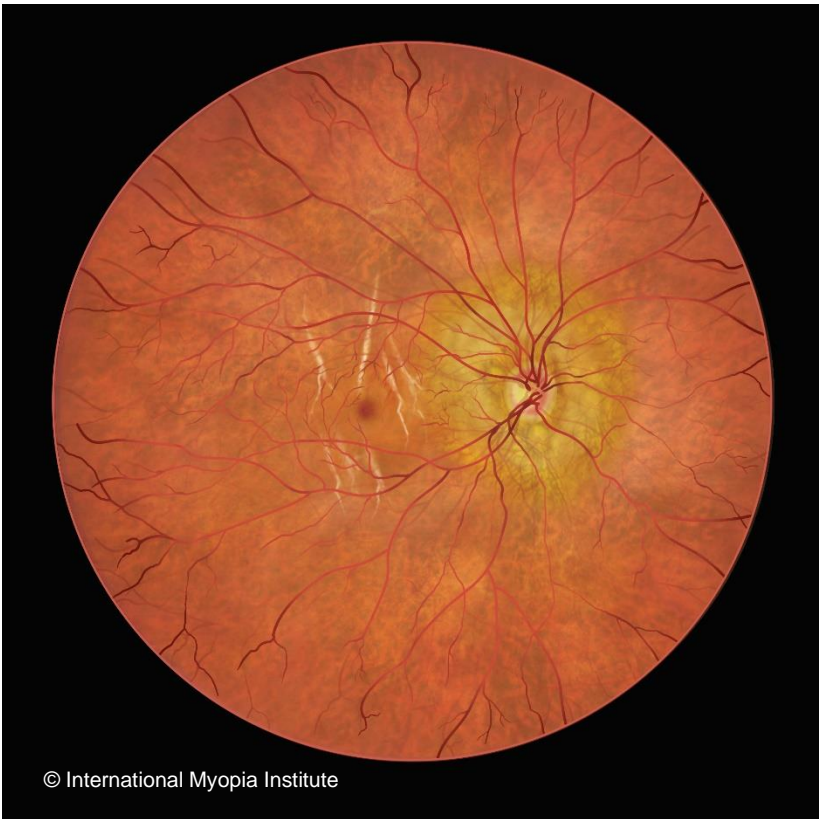© International Myopia Institute

Fuchs spot

**Plus
Lesions**

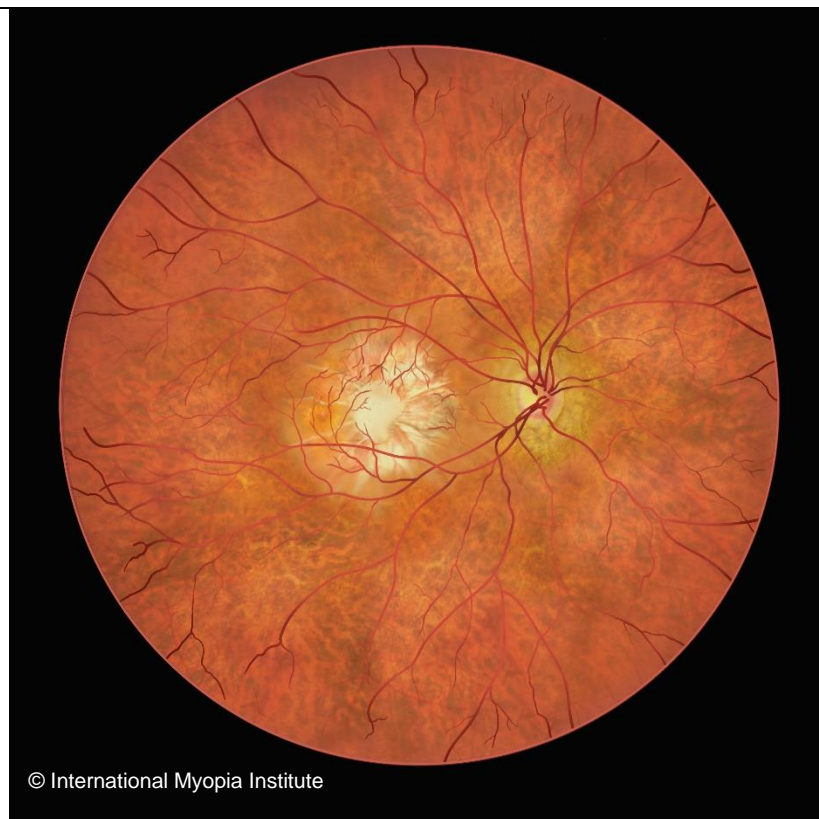

Myopic choroidal neovascularization




Lacquer cracks

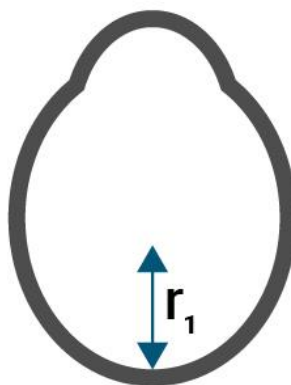
**Posterior
Staphyloma**




A



B



C



ght © International Myopia Institute. All rights reserved.